

Repair of a Comminuted Talar Neck Fracture using ViviGen Formable® Cellular Bone Matrix combined with a SymAlign® Cotton Allograft Wedge

Case performed by: Alaa Mansour, DPM, Timothy Howard, DPM;
Indianapolis, IN, USA

CASE STUDY

Talar neck fractures are uncommon, accounting for <1% of all fractures.¹⁻³ Such fractures are typically the result of high energy trauma and are characterized by displacement, comminution, and soft tissue injury. The talus plays an important role in normal foot ambulation and has a unique extraosseous vascular supply. If left untreated, talar neck fractures can lead to major complications, such as osteonecrosis and post-traumatic arthritis, and long-term morbidity. Treatment of talar neck fractures while avoiding complications presents a unique challenge to surgeons. Particularly in cases with significant bone loss, such as in comminuted talar neck fractures, bone-grafting is a common treatment choice.

One bone grafting option is autograft bone. Autograft bone can provide the osteoconductive, osteoinductive, and osteogenic properties needed for successful bone fusion. However, it is often associated with limitations, including donor-site morbidity and limited quality and supply.⁴ An allograft alternative, ViviGen Formable, also provides all three of these properties while avoiding donor-site morbidity. ViviGen Formable is an osteoconductive scaffold that contains viable cells committed to produce bone in concert with osteoinductive signals naturally found in demineralized bone.

Additionally, because the talus serves as a critical link between the leg and foot¹, restoration of its structural integrity is of utmost importance in repairing talar neck fractures. SymAlign Allograft wedges, with unique texturing and high bone density and strength, were designed specifically to resist graft displacement and endure high compressive force, while maintaining deformity correction.⁵

The following describes the use of ViviGen Formable Cellular Bone Matrix along with SymAlign Cotton Allograft wedge to repair a comminuted talar neck fracture.

Patient

46-year-old male.

The patient presented with an injury to his left ankle following a fall from a 12-foot ladder. The patient recalls his foot getting trapped in one of the ladder steps and twisting. Radiographic and computed tomography (CT) imaging revealed a talar neck fracture spanning from medial to lateral with significant comminution and dislocation of the posterior subtalar joint (Figures 1 & 2). The medial talar neck was noted to have a 6-mm void as well as a varus angulation deformity secondary to the comminution (Figure 1A and B). Laterally, there was impingement of the talus against the lateral malleolus, and two large fracture pieces lodged in the subtalar joint that were preventing reduction of the dislocation (Figure 1C and D).

Procedure

Laterally, open reduction internal fixation (ORIF) was performed to reduce the posterior subtalar dislocation, with plate and screw fixation. Medially, a 6.5mm SymAlign Cotton Allograft wedge was used to correct the varus deformity.

Subsequently, 1cc of ViviGen Formable was packed around the SymAlign wedge and within the bony void (Figure 3). The allografts were secured in place using plate and screw fixation.

Results

At 6 months post-operative, the talar neck fracture had healed with solid osseous consolidation evident on radiographic images (Figure 4). The patient returned to regular shoe gear and was back to daily activities.

Conclusion

This case demonstrates the successful repair of a comminuted talar neck fracture using a combination of a SymAlign Cotton Allograft wedge with ViviGen Formable Cellular Bone Matrix. The strong compressive strength and unique textured design of SymAlign Allograft wedges facilitated the structural repair of the talus, while resisting migration. Concurrently, the use of ViviGen Formable to fill the bony void caused by the comminuted fracture facilitated healing of the fracture due to its osteoconductive, osteoinductive, and osteogenic characteristics.

Results from case studies are not predictive of results in other cases. Results in other cases may vary. Bench/Laboratory testing may not be indicative of clinical outcomes.

Repair of a Comminuted Talar Neck Fracture using ViviGen Formable® Cellular Bone Matrix combined with a SymAlign® Cotton Allograft Wedge

CASE STUDY

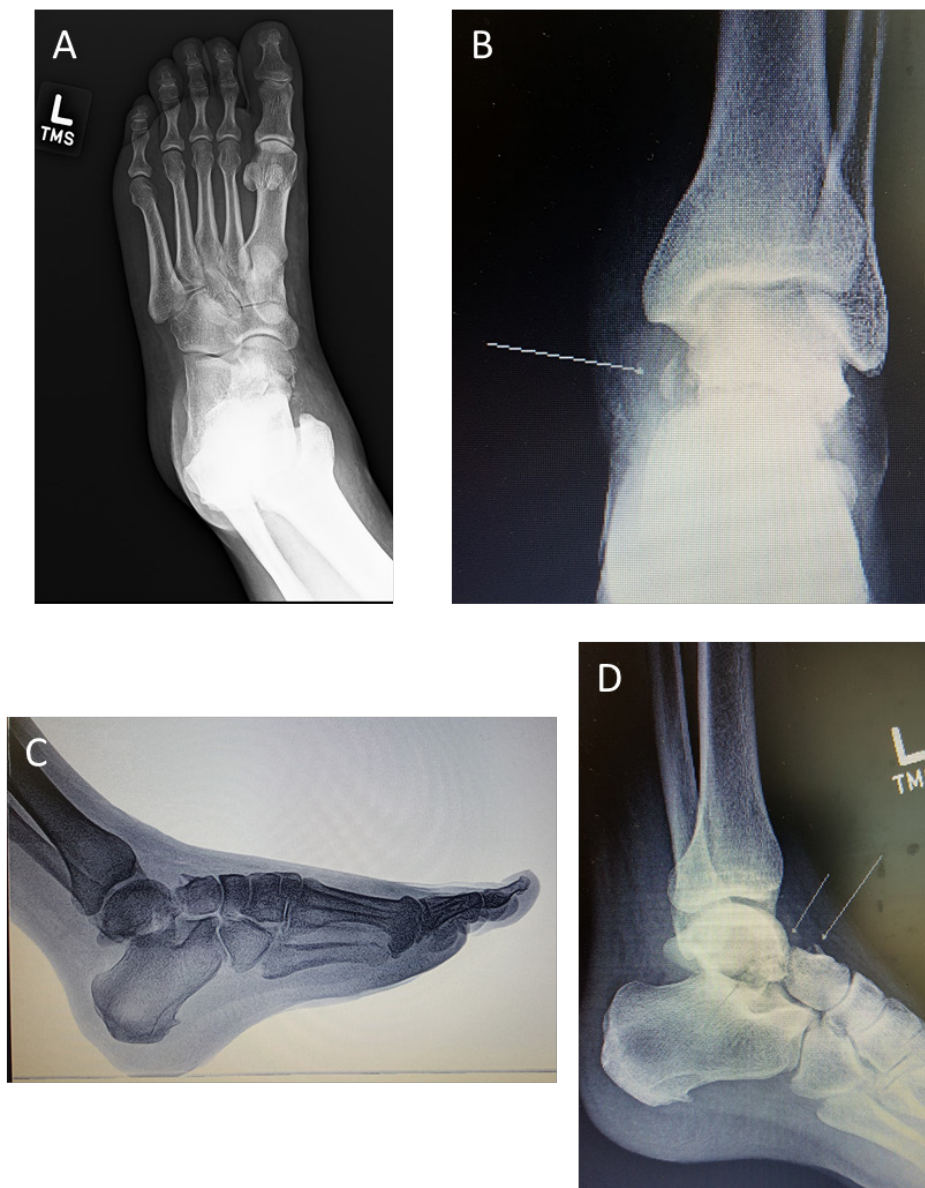

Figure 1.

Radiographic imaging of the left foot revealed a talar neck fracture with posterior subtalar joint dislocation. A varus angulation deformity and a 6mm void (white arrow, B) were evident in the medial talar neck (A and B, respectively). Lateral views revealed impingement of the talus against the lateral malleolus (C) and two large bone fragments lodged in the subtalar joint (D, white arrows).

Results from case studies are not predictive of results in other cases. Results in other cases may vary. Bench/Laboratory testing may not be indicative of clinical outcomes.

Repair of a Comminuted Talar Neck Fracture using ViviGen Formable® Cellular Bone Matrix combined with a SymAlign® Cotton Allograft Wedge

CASE STUDY

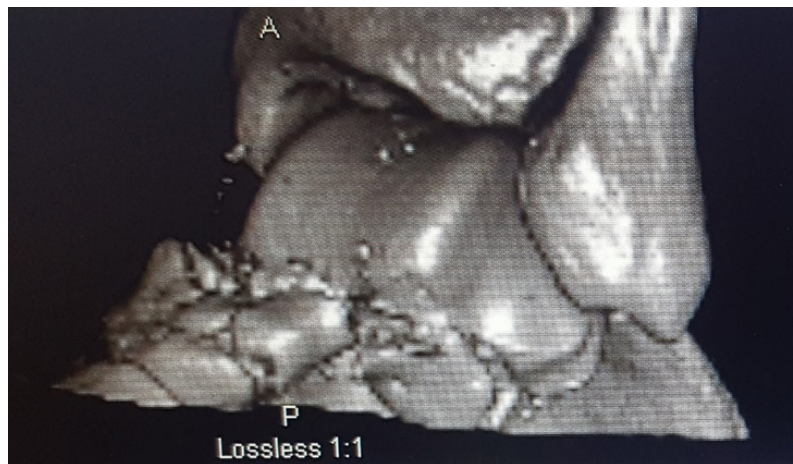

Figure 2.

Computed tomography (CT) images revealed significant comminution of the talar neck.

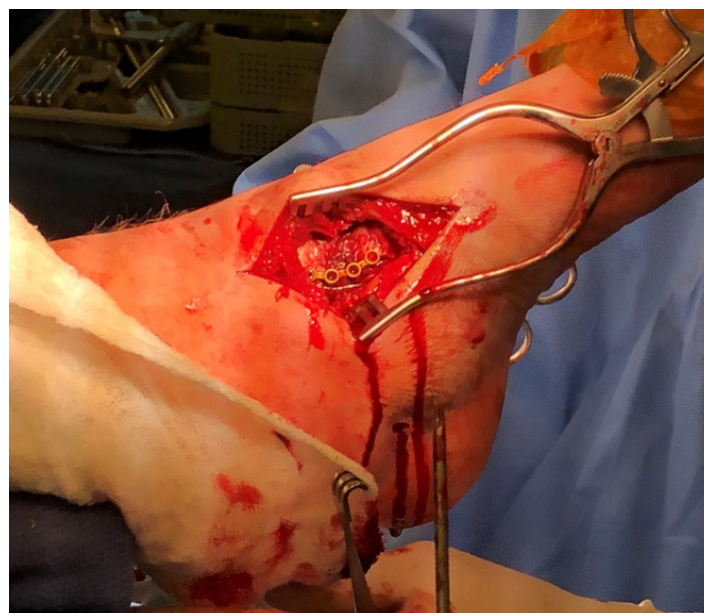


Figure 3.

Intraoperative image showing the medial approach. A SymAlign Cotton Allograft wedge was placed, with ViviGen Formable packed around the graft. The allografts were secured with plate and screw fixation.

Results from case studies are not predictive of results in other cases. Results in other cases may vary. Bench/Laboratory testing may not be indicative of clinical outcomes.

Repair of a Comminuted Talar Neck Fracture using ViviGen Formable® Cellular Bone Matrix combined with a SymAlign® Cotton Allograft Wedge

CASE STUDY

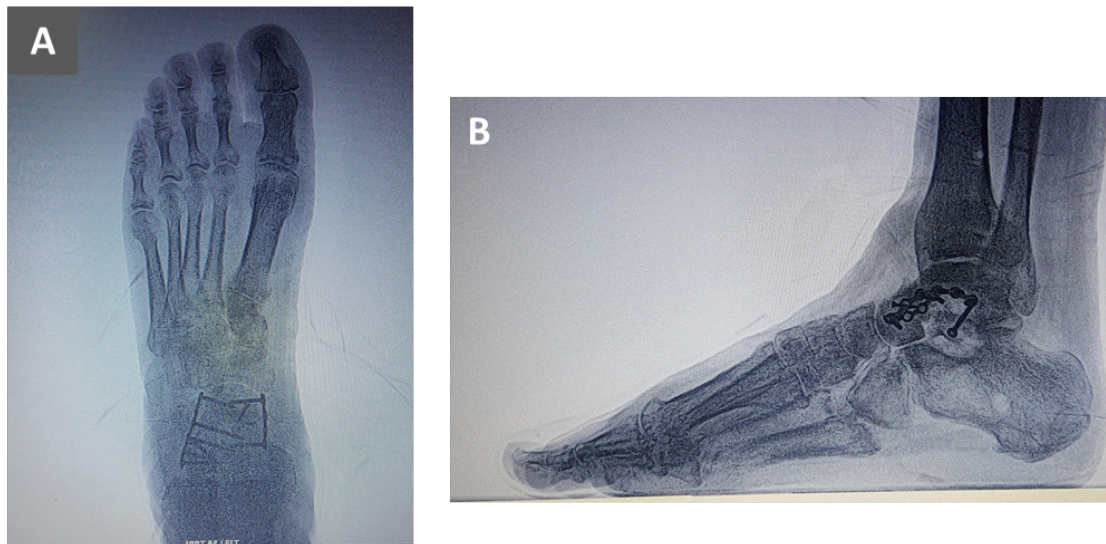


Figure 4.

Radiographic images taken 6 months post-operative revealed solid osseous consolidation of the allografts and full healing of the talar neck fracture.

Results from case studies are not predictive of results in other cases. Results in other cases may vary.
Bench/Laboratory testing may not be indicative of clinical outcomes.

References

1. Melenevsky, Y., Mackey, R. A., Abrahams, R. B. & Thomson, N. B., 3rd. Talar Fractures and Dislocations: A Radiologist's Guide to Timely Diagnosis and Classification. *Radiographics* 35, 765-779, doi:10.1148/rg.2015140156 (2015).
2. Vallier, H. A., Nork, S. E., Barei, D. P., Benirschke, S. K. & Sangeorzan, B. J. Talar neck fractures: results and outcomes. *J Bone Joint Surg Am* 86, 1616-1624 (2004).
3. Halvorson, J. J., Winter, S. B., Teasdall, R. D. & Scott, A. T. Talar neck fractures: a systematic review of the literature. *J Foot Ankle Surg* 52, 56-61, doi:10.1053/j.jfas.2012.10.008 (2013).
4. Khan, W. S., Rayan, F., Dhinsa, B. S. & Marsh, D. An osteoconductive, osteoinductive, and osteogenic tissue-engineered product for trauma and orthopaedic surgery: how far are we? *Stem Cells Int* 2012, 236231, doi:10.1155/2012/236231 (2012).
5. Data on file LifeNet Health, 68-20-198.

LifeNet Health helps to save lives, restore health and give hope to thousands of patients each year. We are the world's most trusted provider of transplant solutions, from organ procurement to new innovations in bio-implant technologies and cellular therapies—a leader in the field of regenerative medicine, while always honoring the donors and healthcare professionals that allow the healing process.

LifeNetHealth.org

LifeNet Health, the LifeNet Health logo, ViviGen Formable, and SymAlign are registered trademarks of LifeNet Health.

©2019 LifeNet Health, Virginia Beach, VA. All rights reserved.
68-20-257.00

The third party trademarks used herein are the trademarks of their respective owners.
©DePuy Synthes 2019. All rights reserved.
120343-190807 DSUS